Aortic dissection presenting as an ECG disturbance

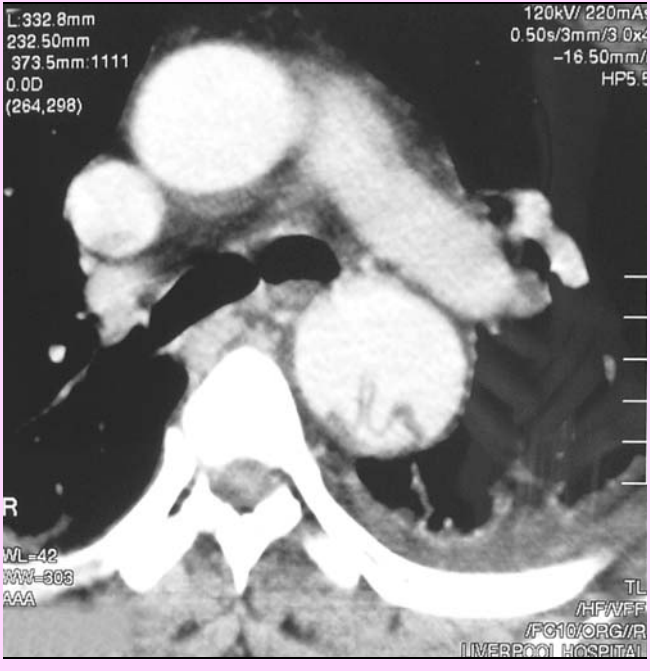

WHEN A 46-YEAR-OLD MAN presented with chest pain, the key to the diagnosis was in his ECG tracing — the one on his thoracic CT scan, that is!

Andrew Bonura
Radiology Registrar
Liverpool Hospital, NSW